

## PATCH ESOPHAGOPLASTY USING AN IN-BODY-TISSUE-ENGINEERED COLLAGENOUS CONNECTIVE TISSUE MEMBRANE, “BIOSHEET”, IN A BEAGLE MODEL: A NOVEL ESOPHAGEAL SCAFFOLD

Hiroomi Okuyama<sup>1</sup>, Satoshi Umeda<sup>1</sup>, Yuichi Takama<sup>1</sup>, Takeshi Terasawa<sup>2</sup>, Yasuhide Nakayama<sup>2</sup>  
<sup>1</sup>Osaka University Graduate School of Medicine, Suita, Osaka, Japan, <sup>2</sup>National Cerebral and Cardiovascular Centre Research Institute, Suita, Osaka, Japan

**Aim:** Although many approaches to esophageal replacement have been investigated, these efforts have thus far only met limited success. In-body-tissue-engineered connective tissue tubes have been reported to be effective as vascular replacement grafts. The aim of this study was to investigate the usefulness of an in-body-tissue-engineered collagenous connective tissue membrane, “BIOSHEET”, as a novel esophageal scaffold in a beagle model.

**Methods:** We prepared BIOSHEETs by embedding specially designed molds into subcutaneous pouches in beagles. After 1-2 months, the molds, which were filled with ingrown connective tissues, were harvested to obtain the BIOSHEETs. Rectangular-shaped BIOSHEETs (10x20mm) were implanted to replace the defects of the same size, which were created in the cervical esophagus of beagles. Endoscopic evaluation was performed at 4 and 12 weeks after implantation. The esophagus, including the BIOSHEET was harvested and subjected to a histological evaluation at 4 weeks (n=2) and 12 weeks (n=2) after implantation. The animal study protocols were approved by the National Cerebral and Cardiovascular Centre Research Institute Committee (No. 16048).

**Results:** The BIOSHEETs showed sufficient strength and flexibility to replace the esophagus defect. All animals survived with full oral feeding during the study period. No anastomotic leakage was observed. An endoscopic study at 4 and 12 weeks after implantation revealed that the anastomotic sites and the internal surface of the BIOSHEET were smooth, without stenosis. A histological analysis at 4 weeks after implantation demonstrated that stratified squamous epithelium was regenerated on the internal surface of BIOSHEET. A histological analysis at 12 weeks after implantation demonstrated the regeneration of muscle tissue in the implanted BIOSHEET (Figure).

**Conclusion:** The long-term results of patch esophagoplasty using BIOSHEETs revealed the regeneration of stratified squamous epithelium and muscular tissues in the implanted sheets. These results suggest that BIOSHEETs are useful as a novel esophageal scaffold.

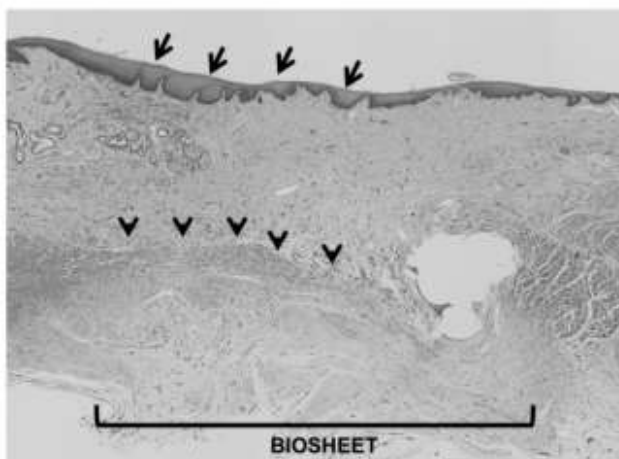


Figure: Stratified squamous epithelium (arrow) and muscular tissue (arrowhead) were found in the BIOSHEET at 12 weeks after implantation.